

Acne Vulgaris Is a Special Clinical Type of Pellagra

Jiang Hao^{1,*}, Li Changyi²

¹Research Department, The first Hospital of Guangxi University of Chinese Medicine, Nanning City, China

²Dermatological Department, The first Hospital of Guangxi University of Chinese Medicine, Nanning City, China

Email address:

Johnjianghao2005@126.com (Jiang Hao)

*Corresponding author

To cite this article:

Jiang Hao, Li Changyi. Acne Vulgaris Is a Special Clinical Type of Pellagra. *American Journal of Clinical and Experimental Medicine*. Vol. 9, No. 6, 2021, pp. 204-208. doi: 10.11648/j.ajcem.20210906.13

Received: November 3, 2021; **Accepted:** November 22, 2021; **Published:** November 24, 2021

Abstract: *Background:* Acne, the most common skin disease characterized by comedones, papules, pustules, nodules, and/or cysts, has a prevalence of 90% during adolescence. The pathogenesis of acne vulgaris requires further study based on the pathological and pathophysiological changes in acne. *Recent findings and evidence:* Adolescence is the period when teenagers have very high nutritional demands. The occurrence of acne during adolescence suggests that the patient is nutritionally deficient or has increased nutritional requirements. Malnutrition of vitamins (niacin) is the most important cause of abnormal metabolism and inflammation. A pellagra diagnosis should focus on the presence of the “3 D’s” (diarrhea, dermatitis and dementia). The clinical features of acne include “3 D’s”: dermatitis (acne, seborrheic dermatitis), dyspepsia, and depression. Patients with acne are frequently associated with abnormal serum lipid profiles and elevated sebum secretion. Foam cells are an important pathological change in acne lesions. Niacin is the only vitamin that promotes the efflux of cholesterol and other lipids from cells and prevents foam cell formation. Foam cells in acne lesions suggest that patients with acne are deficient in niacin. Recently, several studies have reported the efficacy and safety of nicotinamide and niacin for acne treatment. *Summary:* Based on an analysis of the clinical feature of acne patients, pathological changes in acne lesions and the therapeutic effects of niacin on acne, we propose that acne can be diagnosed as a specific clinical type of pellagra, and niacin is the first choice for the treatment of acne vulgaris.

Keywords: Acne, Niacin, Nicotinamide, Pellagra, Vitamin B3

1. Introduction

Pellagra is a systemic disease resulting from a marked chronic deficiency of Vitamin B3 (niacin) and/or nicotinamide [1-3]. Niacin and nicotinamide are precursors of coenzyme I (the oxidized form of nicotinamide adenine dinucleotide (NAD)) and coenzyme II (the reduced form of nicotinamide adenine dinucleotide phosphate (NADP)), which either donate or accept hydrogen ions in vital oxidation-reduction reactions [1-3]. A pellagra diagnosis should focus on the presence of the “3 D’s” (diarrhea, dermatitis and dementia), localization and seasonal appearance. However, the three classic symptoms do not always appear on a patient at the same time; they can appear along a continuum for many patients. Moreover, there are no chemical tests available to definitively diagnose pellagra [1]. If a pellagra patient had symptoms of dementia, it is difficult

to alleviate the condition, because his nervous tissues in brain may have been damaged. The current diagnostic approach to pellagra does not provide a basis for early warning, definitive diagnosis, timely treatment, nor prevent pellagra from deteriorating and aggravating. Medical doctor cannot diagnose a patient as mild and moderate pellagra clearly.

Why does niacin deficiency cause inflammation? The pathogenesis of pellagra has not yet been fully elucidated. If a pellagra patient had symptoms of dementia, it would be difficult to alleviate the condition because the nervous tissues in the brain may have been damaged. The current diagnostic approach to pellagra does not provide a basis for early warning, definitive diagnosis, timely treatment, or prevention of pellagra from deterioration and aggravation. Medical doctors cannot clearly diagnose patients with mild or

moderate pellagra.

Acne vulgaris is a skin disorder of the sebaceous follicles that commonly occurs in adolescence and young adulthood [4]. Acne is a chronic systemic disease. Acne is a cardinal component of many systemic diseases or syndromes, such as congenital adrenal hyperplasia, polycystic ovarian syndrome, and Apert syndrome [5]. Adolescence is a critical period of growth and development, and the requirement for nutrition is the most in this stage of life, making young people susceptible to malnutrition [6]. Clinically, niacin is effective in the treatment of acne. We believe that acne can be diagnosed as a special type of pellagra, because the demands for niacin in acne patients are increasing, and even serum nicotinamide concentrations of acne patients are in the normal range. This is a type of pellagra that is not necessarily accompanied by diarrhea and dementia. However, this type of pellagra (acne vulgaris) may cause mental illness such as depression, and in extreme cases, schizophrenia or thoughts of suicide.

Pellagra is characterized by the “3 D’s”: dermatitis, diarrhea, and dementia. The clinical features of acne include 3 D’s: dermatitis (acne, seborrheic dermatitis), dyspepsia, and depression. Pellagra has another “D”: death. Acne lacks the fourth “D,” but it has an “S”: suicide [7-9]. Some patients with acne committed suicide and died.

2. Dermatitis and Inflammation of Acne

Pellagra skin lesions usually occur on areas more prone to sun exposure, whereas acne lesions are always on the face, back, neck and chest [10], which are also prone to sun exposure. Both pellagra and acne lesions are distributed symmetrically. Pathological changes common to both diseases include sebaceous gland hyperplasia and prominent seborrhoea, vascular dilatation, endothelial cell proliferation, inflammatory cell infiltration, hyper-keratinization and subsequent desquamation of the stratum corneum, necrosis, and atrophic and apoptotic epidermis [11, 12]. Dermatitis is mild inflammation on the skin surface. The inflammation of acne occurs in the closed follicle ducts and presents pathological changes which are different from Dermatitis, such as comedo, papules, abscesses, pustules, cysts. But the mechanism of inflammation of dermatitis and acne vulgaris is the same. The energy generated from oxidation of carbohydrates and proteins in cells cannot be converted into ATP for cells due to niacin deficiency, but transfer into free radicals (ROS and RNS) damage normal tissue cells and cause inflammation.

3. Pellagra, Acne and Depression

Niacin deficiency leads to abnormal ATP synthesis and brain energy supply disorder, but most patients' brain function will not seriously impair dementia immediately. It takes a long time for pellagra patients to develop dementia. Before the onset of dementia symptoms, pellagra patients have clear minds, but they are accompanied by adverse

emotional and psychological changes such as depression, apathy, despair, irritability, anorexia, poor appetite, distress and sadness, insomnia, anxiety, fear, memory decline, inability of logical thinking and so on [13-17]. Patients with chronic acne have negative psychological symptoms. Acne vulgaris is associated with social isolation, employment difficulties, depression, and suicide [8, 18-20]. With time, the inflammation of acne vulgaris disappeared, while depression might still exist. Patients with acne had greater impairment in mental health scores than those with asthma, epilepsy, diabetes, back pain, arthritis, or coronary artery disease [21]. Furthermore, acne patients reported higher depression and anxiety scores than patients with psoriasis and those attending oncology or general dermatology clinics [8, 22]. Nevertheless, depression is not just a psychological, but an inflammatory disease. Depressed patients have been found to have higher levels of proinflammatory cytokines, acute-phase proteins, chemokines, and cellular adhesion molecules [23].

Without effective treatment and with increasing age, worsening of depression could lead to mental disorders, including schizophrenia and dementia [24, 25]. The prevalence of acne in young adults was > 90%. The patient with acne had no dementia; Dementia is rare among young people, but symptoms of schizophrenia develop in young adults. The median prevalence of schizophrenia was 4.6/1,000 for point prevalence, 3.3/1,000 for period prevalence, 4.0/for lifetime prevalence, and 7.2/for lifetime morbid risk [26, 27].

Niacin has been found to cure, or at least improve, symptoms of depression, migraine, cognitive decline, schizophrenia, Parkinson's disease, and dementia (e.g., Alzheimer's disease) [28, 29]. Niacin deficiency leads to abnormal oxidative phosphorylation, decreased ATP synthesis, and ATP deficiency, and the energy produced by the oxidation of carbohydrates in the form of free radicals disturbs the function of nerve cells and damages nerve cells, which may be the most important mechanism of depression and other central nervous system diseases. Gene mutation, called PTEN, which is believed to cause familial Alzheimer's, may also cause acne [30]. Niacin plays an important role in DNA replication, repair, and cell differentiation [31]. The role of niacin in relation to DNA (such as PTEN) repairing, genomic stability, and prevention of mutagenesis could be investigated [32].

4. Pellagra, Acne and Dyspepsia

Chronic or recurrent diarrhea is a symptom of dyspepsia in the pellagra. Other gastrointestinal disturbances include anorexia, nausea, and epigastric discomfort [33]. Acne vulgaris and acne rosacea are also frequently accompanied by gastrointestinal disturbances, of which constipation is most frequently recorded, and less often, (so-called dyspepsia or indigestion) [34-37]. Approximately 68.5% of acne patients display symptoms of functional dyspepsia or gastrointestinal disorders, including halitosis, distension, pain, belching, acid reflux, diarrhea, and constipation [38]. Certain patients with

acne vulgaris have decreased, while others have increased gastric acidity and indigestion [29, 39]. Nicotinamide deficiency in humans may also contribute to increased frequency of gastrointestinal cancers in certain populations, although other micronutrient deficiencies are likely to be involved as well [40]. Niacin is an effective drug for the treatment of hypochlorhydria in functional dyspepsia [31, 41]. Acne associated with functional dyspepsia symptoms could be considered a deficiency of niacin, as could dyslipidemia [42], a variety of food-induced types of indigestion, and gastrointestinal dynamics disorders. Niacin deficiency leads to a shortage of energy (ATP) [1]. ATP deficiency leads to disorders of DNA, proteins, enzymes (such as Na⁺-K⁺-ATP enzyme, H⁺-K⁺-ATP enzyme, and digestive enzymes), hormone synthesis, regulation, and physiological activity, as well as smooth muscle motility and immune system function. Gastrointestinal symptoms caused by niacin deficiency can easily be misdiagnosed. The relationship between acne and gastrointestinal diseases requires further study.

5. Foam Cells in Acne Lesions (Figure 1)

Foam cells are the hallmark cells of atherosclerosis [43]. Foam cells are also the main pathological changes in acne vulgaris, which indicates that atherosclerotic inflammation caused by abnormal lipid oxidation in the follicle duct is purulent acne. Acne is not a skin disease induced by infection, because no bacteria, fungi or parasites can be seen in early phase of acne lesion. The foam cells in acne lesions are macrophages and neutrophils that have phagocytosed large amounts of lipids [43]. Foam cell formation in acne lesions not only indicates abnormal lipid metabolism, but also suggests abnormal immune functions. Macrophages and neutrophils unable to deal with the swallowed sebum and lipids. Foam cells are also a sign of niacin deficiency and suggest the need for niacin treatment, because niacin is the only vitamin that can promote the efflux of oxidized lipids from foam cells [44-47].

6. Niacin in Acne Treatment

Niacin, also known as nicotinic acid, is the most critical vitamin that promotes lipid metabolism, inhibits inflammation and antioxidant, and prevents foam cell formation [48-51]. Both niacin and nicotinamide are precursors for NAD and NADP and identical in their vitamin activity, but nicotinamide does not have the same pharmacological, lipid modifying effects as niacin. Recently, several studies regarding the efficacy and safety of nicotinamide for acne treatment were published [52-58]. The mechanism of niacin in the treatment of acne is to promote the energy of nutrient (lipid, sugar and protein) in cells via oxidative phosphorylation to form ATP utilized by normal cells, rather than generate ROS and RNS to damage to cells [59]. A pilot study shows that the effective rate of high dose niacin in 3 month treatment of acne vulgaris up to 80% [60]. The therapeutic effect of niacin on acne is an important basis for acne to be diagnosed as pellagra.

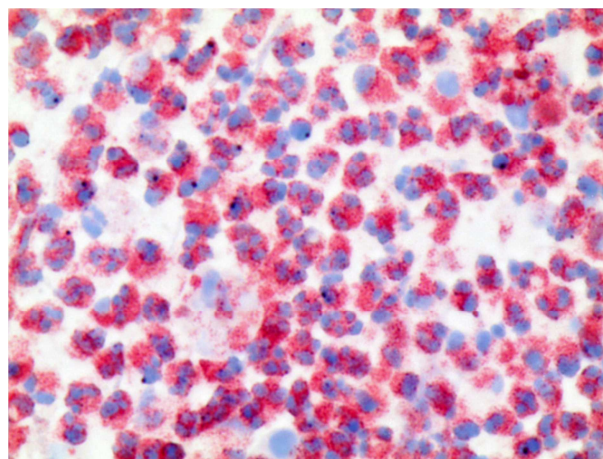


Figure 1. Foam cell in acne lesion.

Oil Red O and hematoxylin staining (Olympus BX43, 40×10. The samples were collected from a 19-year-old male patient with acne. Ethical approval was obtained from the ethics committee of the First Affiliated Hospital of Guangxi University of Chinese Medicine.

7. Conclusion

According to the clinical feature of acne patients, pathological changes of acne lesions and the therapeutic effect of niacin, we proposed that acne vulgaris is a special clinical type of pellagra that is not necessarily accompanied by diarrhea and dementia, even if the concentration of plasma nicotinamide in acne patients are in the normal range. Although the proposal requires more scientific research, niacin is essential for mild, moderate and severe acne treatment. Acne patients may also have deficiencies in protein and other vitamins and trace elements. Nutritional assessment and monitoring protocols should be developed for neonatal, infantile, children, adolescent and pregnant acne patients. Supplement of niacin and other nutrients may promote the healthy growth and improve the quality of life of acne patients.

Abbreviations

ATP: adenosine triphosphate
 NAD: nicotinamide adenine dinucleotide
 NADP: nicotinamide adenine dinucleotide phosphate
 RNS: Reactive nitrogen species
 ROS: reactive oxygen species

References

- [1] Hegyi J, Schwartz RA, Hegyi V. Pellagra: dermatitis, dementia, and diarrhea. *Int J Dermatol.* 2004 Jan; 43 (1): 1-5.
- [2] Brown TM. Pellagra: an old enemy of timeless importance. *Psychosomatics.* 2010 Mar-Apr; 51 (2): 93-7.
- [3] Rajakumar K. Pellagra in the United States: a historical perspective. *South Med J.* 2000 Mar; 93 (3): 272-7.

- [4] Toyoda M, Morohashi M. Pathogenesis of acne. *Med Electron Microsc.* 2001 Mar; 34 (1): 29–40.
- [5] Zouboulis CC. Acne as a chronic systemic disease. *Clin Dermatol.* 2014 May–Jun; 32 (3): 389–96.
- [6] Jacob JA, Nair MK. Protein and micronutrient supplementation in complementing pubertal growth. *Indian J Pediatr.* 2012 Jan; 79 (Suppl 1): S84–91.
- [7] Halvorsen JA, Stern RS, Dalgard F, Thoresen M, Bjertness E, Lien L. Suicidal ideation, mental health problems, and social impairment are increased in adolescents with acne: a population-based study. *J Invest Dermatol.* 2011 Feb; 131 (2): 363-70. Epub 2010 Sep 16.
- [8] Samuels DV, Rosenthal R, Lin R, Chaudhari S, Natsuaki MN. Acne vulgaris and risk of depression and anxiety: A meta-analytic review. *J Am Acad Dermatol.* 2020 Aug; 83 (2): 532-541.
- [9] Uhlenhake E, Yentzer BA, Feldman SR. Acne vulgaris and depression: a retrospective examination. *J Cosmet Dermatol.* 2010 Mar; 9 (1): 59-63.
- [10] Elman M, Lebzelter J. Light therapy in the treatment of acne vulgaris. *Dermatol Surg.* 2004 Feb; 30 (2 Pt 1): 139–46.
- [11] Leyden JJ. Therapy for acne vulgaris. *N Engl J Med.* 1997; 336 (16): 1156–62.
- [12] Wan P, Moat S, Anstey A. Pellagra: a review with emphasis on photosensitivity. *Br J Dermatol.* 2011 Jun; 164 (6): 1188–200.
- [13] R Dodel, G Deuschl. Demenzfrüherkennung: nur zerstreut oder schon krank? Early diagnosis of dementia: Kognitive Defizite. *MMW Fortschritte der Medizin*, 2020, 162 (6): 60-68.
- [14] Deardorff WJ, Grossberg GT. Behavioral and psychological symptoms in Alzheimer's dementia and vascular dementia. *Handb Clin Neurol.* 2019; 165: 5-32.
- [15] Bondi MW, Edmonds EC, Salmon DP. Alzheimer's Disease: Past, Present, and Future. *J Int Neuropsychol Soc.* 2017 Oct; 23 (9-10): 818-831.
- [16] Barrah S, Jebali H, Kheder R, Krid M, Smaoui W, Beji S, Hmida FB, Fatma LB, Rais L, Zouaghi MK. Pellagra Disease in a Hemodialysis Patient. *Saudi J Kidney Dis Transpl.* 2020 Jul-Aug; 31 (4): 874-876.
- [17] Sood S, Jafferany M, Vinaya Kumar S. Depression, psychiatric comorbidities, and psychosocial implications associated with acne vulgaris. *J Cosmet Dermatol.* 2020 Dec; 19 (12): 3177-3182.
- [18] Tan JK. Psychosocial Impact of Acne Vulgaris: Evaluating the Evidence. *Skin Therapy Lett.* 2004; 9 (7): 1-3, 9.
- [19] Hazarika N, Archana M. The Psychosocial Impact of Acne Vulgaris. *Indian J Dermatol.* 2016 Sep-Oct; 61 (5): 515-20. doi: 10.4103/0019-5154.190102. PMID: 27688440; PMCID: PMC5029236.
- [20] Cengiz GF, Gürel G. Difficulties in emotion regulation and quality of life in patients with acne. *Qual Life Res.* 2020 Feb; 29 (2): 431-438.
- [21] Awad SM, Morsy H, Sayed AA, Mohamed NA, Ezzat GM, Noaman MM. Oxidative stress and psychiatric morbidity in patients with facial acne. *J Cosmet Dermatol.* 2018 Apr; 17 (2): 203-208.
- [22] Tan JK. Psychosocial impact of acne vulgaris: evaluating the evidence. *Skin Therapy Lett.* 2004 Aug-Sep; 9 (7): 1-3, 9. PMID: 15334275.
- [23] Raison CL, Capuron L, Miller AH. Cytokines sing the blues: inflammation and the pathogenesis of depression. *Trends Immunol.* 2006; 27 (1): 24-31.
- [24] Ting C, Rajji TK, Ismail Z, Tang-Wai DF, Apanasiewicz N, Miranda D, Mamo D, Mulsant BH. Differentiating the cognitive profile of schizophrenia from that of Alzheimer disease and depression in late life. *PLoS One.* 2010; 5 (4): e10151.
- [25] A. F. Jorm. Is depression a risk factor for dementia or cognitive decline? *Gerontology* 2000; 46: 219-227.
- [26] Dinesh Bhugra. The global prevalence of schizophrenia. *PLoS Med.* 2005 May; 2 (5): e151.
- [27] Harrop C, Trower P. Why does schizophrenia develop at late adolescence? *Clin Psychol Rev.* 2001 Mar; 21 (2): 241-65.
- [28] Hoffer LJ. Vitamin therapy in schizophrenia. *Isr J Psychiatry Relat Sci.* 2008; 45 (1): 3-10.
- [29] Morris MC, Evans DA, Bienias JL, Scherr PA, Tangney CC, Hebert LE, Bennett DA, Wilson RS, Aggarwal N. Dietary niacin and the risk of incident Alzheimer's disease and of cognitive decline. *J Neurol Neurosurg Psychiatry.* 2004, 75 (8): 1093-9.
- [30] Wang B, Yang W, Wen W, Sun J, Su B, Liu B, Ma D, Lv D, Wen Y, Qu T, Chen M, Sun M, Shen Y, Zhang X. Gamma-secretase gene mutations in familial acne inversa. *Science.* 2010 Nov 19; 330 (6007): 1065.
- [31] Devita Surjana, Gary M. Halliday, Diona L. Damian. Role of nicotinamide in DNA damage, mutagenesis, and DNA repair. *J Nucleic Acids.* 2010; 2010: 157591.
- [32] Benavente CA, Jacobson MK, Jacobson EL. NAD in skin: therapeutic approaches for niacin. *Curr Pharm Des.* 2009; 15 (1): 29-38.
- [33] Pitche PT. Pellagra. *Sante.* 2005; 15 (3): 205-8.
- [34] Haber R, El Gemayel M. Comorbidities in rosacea: A systematic review and update. *J Am Acad Dermatol.* 2018 Apr; 78 (4): 786-792. e8.
- [35] Lim HG, Fischer A, Rueda MJ, Kendall J, Kang S, Chien AL. Prevalence of gastrointestinal comorbidities in rosacea: Comparison of subantimicrobial, modified release doxycycline versus conventional release doxycycline. *J Am Acad Dermatol.* 2018 Feb; 78 (2): 417-419.
- [36] Yang X. Relationship between *Helicobacter pylori* and Rosacea: review and discussion. *BMC Infect Dis.* 2018 Jul 11; 18 (1): 318.
- [37] Lu CY, Hsieh MS, Wei KC, Ezmerli M, Kuo CH, Chen W. Gastrointestinal involvement of primary skin diseases. *J Eur Acad Dermatol Venereol.* 2020 Dec; 34 (12): 2766-2774.
- [38] Jiang Hao, Li Changyi. A preliminary investigation of acne vulgaris associated with dyspepsia. *Chinese Journal of Aesthetic Medicine.* 2010. 19 (7): 1049-1051.

- [39] Zanchi C, Pintaldi S, Di Leo G, Ronfani L, Zamagni G, Viel M, Barbi E, Cozzi G. Fifteen-Years Follow-Up in a Cohort of Children with Functional Gastrointestinal Disorders: Prevalence and Risk Factors to Develop Neuropsychiatric Disorders and Other Comorbidities. *Children (Basel)*. 2021 Sep 24; 8 (10): 838.
- [40] Savvidou S. Pellagra: a non-eradicated old disease. *Clin Pract*. 2014 Apr 28; 4 (1): 637. doi: 10.4081/cp.2014.637. PMID: 24847436; PMCID: PMC4019925.
- [41] Jonathan E. Prousky, Claire Kerwin. Niacin (Nicotinic Acid) a Putative Treatment for Hypochlorhydria: Re-analysis of Two Case Reports. *Journal of Orthomolecular Medicine*, 2002, 17 (3).
- [42] Jiang H, Li C, Zhou L, Lu B, Lin Y, Huang X, Wei B, Wang Q, Wang L, Lu J. Acne patients frequently associated with abnormal plasma lipid profile. *Journal of Dermatology*. 2015, 42 (3): 296-299.
- [43] Hao Jiang, Changyi Li. Common Pathogenesis of Acne Vulgaris and Atherosclerosis. *Inflammation*. 2019 Feb; 42 (1): 1-5.
- [44] Wu ZH, Zhao SP. Niacin promotes cholesterol efflux through stimulation of the PPARgamma-LXRalpha -ABCA1 pathway in 3T3-L1 adipocytes. *Pharmacology*. 2009; 84 (5): 282-7.
- [45] Yvan-Charvet L, Kling J, Pagler T, Li H, Hubbard B, Fisher T, Sparrow CP, Taggart AK, Tall AR. Cholesterol efflux potential and antiinflammatory properties of high-density lipoprotein after treatment with niacin or anacetrapib. *Arterioscler Thromb Vasc Biol*. 2010 Jul; 30 (7): 1430-8.
- [46] Huang H, Koelle P, Fendler M, Schroettle A, Czihal M, Hoffmann U, Kuhlencordt PJ. Niacin reverses migratory macrophage foam cell arrest mediated by oxLDL in vitro. *PLoS One*. 2014 Dec 18; 9 (12): e114643.
- [47] Ronsein GE, Hutchins PM, Isquith D, Vaisar T, Zhao XQ, Heinecke JW. Niacin Therapy Increases High-Density Lipoprotein Particles and Total Cholesterol Efflux Capacity But Not ABCA1-Specific Cholesterol Efflux in Statin-Treated Subjects. *Arterioscler Thromb Vasc Biol*. 2016 Feb; 36 (2): 404-11.
- [48] Ganji SH, Kashyap ML, Kamanna VS. Niacin inhibits fat accumulation, oxidative stress, and inflammatory cytokine IL-8 in cultured hepatocytes: Impact on non-alcoholic fatty liver disease. *Metabolism*. 2015 Sep; 64 (9): 982-90.
- [49] Ganji SH, Qin S, Zhang L, Kamanna VS, Kashyap ML. Niacin inhibits vascular oxidative stress, redox-sensitive genes, and monocyte adhesion to human aortic endothelial cells. *Atherosclerosis*. 2009 Jan; 202 (1): 68-75.
- [50] Chai JT, Digby JE, Ruparelia N, Jefferson A, Handa A, Choudhury RP. Nicotinic acid receptor GPR109A is down-regulated in human macrophage-derived foam cells. *PLoS One*. 2013 May 2; 8 (5): e62934. doi: 10.1371/journal.pone.0062934. Print 2013.
- [51] Ying Zhu, Ke-ke Zhao, Yao Tong, Ya-li Zhou, Yi-xiao Wang, Pei-quan Zhao, Zhao-yang Wang. Exogenous NAD⁺ decreases oxidative stress and protects H₂O₂-treated RPE cells against necrotic death through the up-regulation of autophagy. *Sci Rep*. 2016; 6: 26322.
- [52] Walocko FM, Eber AE, Keri JE, Al-Harbi MA, Nouri K. The role of nicotinamide in acne treatment. *Dermatol Ther*. 2017 Feb 21.
- [53] Chen AC, Damian DL. Nicotinamide and the skin. *Australas J Dermatol*. 2014 Aug; 55 (3): 169-75.
- [54] Forbat E, Al-Niaimi F, Ali FR. Use of nicotinamide in dermatology. *Clin Exp Dermatol*. 2017 Mar; 42 (2): 137-44.
- [55] Niren NM, Torok HM. The Nicomide Improvement in Clinical Outcomes Study (NICOS): results of an 8-week trial. *Cutis*. 2006; 77 (Suppl 1): 17-28.
- [56] Khodaeiani E, Fouladi RF, Amirnia M, Saeidi M, Karimi ER. Topical 4% nicotinamide vs. 1% clindamycin in moderate inflammatory acne vulgaris. *Int J Dermatol*. 2013 Aug; 52 (8): 999-1004.
- [57] Rolfe HM. A review of nicotinamide: treatment of skin diseases and potential side effects. *J Cosmet Dermatol*. 2014 Dec; 13 (4): 324-8.
- [58] Fivenson DP. The mechanisms of action of nicotinamide and zinc in inflammatory skin disease. *Cutis*. 2006 Jan; 77 (Suppl 1): 5-10.
- [59] Di Meo S, Reed TT, Venditti P, Victor VM. Role of ROS and RNS Sources in Physiological and Pathological Conditions. *Oxid Med Cell Longev*. 2016; 2016: 1245049.
- [60] Hao J, Changyi L. High dose niacin in the treatment of acne vulgaris: a pilot study. *Chin J Aesthet Med*. 2016; 25 (12): 54-9.